

ASNC CARDIAC AMYLOIDOSIS PRACTICE POINTS UPDATE

^{99m}Techetium- Pyrophosphate Imaging for Transthyretin Cardiac Amyloidosis

^{99m}Techetium-Pyrophosphate Imaging for Transthyretin Cardiac Amyloidosis

OVERVIEW

The purpose of this document is to identify the critical components involved in performing ^{99m}Techetium-pyrophosphate (^{99m}Tc-PYP) imaging for the evaluation of cardiac transthyretin amyloidosis (ATTR).

BACKGROUND

- The majority of individuals with cardiac amyloidosis have myocardial amyloid deposits formed from misfolded light chain (AL) or transthyretin (TTR) proteins. Diagnosis of amyloidosis and differentiation between the types is important for prognosis, therapy, and genetic counseling.
- Cardiac ATTR amyloidosis, the focus of this practice points document, is an under diagnosed cause of heart failure.
- Amyloid derived from wild-type TTR results in a restrictive cardiomyopathy, most commonly presenting in men in their early 70s onwards, but occasionally seen as young as age 60. Although almost 1 in 4 males > 80 years have some TTR-derived amyloid deposits at autopsy, the clinical significance of a mild degree of deposition is unknown--generally clinical manifestations of heart failure occur once enough amyloid has been deposited to cause LV wall thickening (1).
- Approximately 3 – 4% among US African Americans have a common inherited mutation of the TTR gene (Val122Ile), which produces a restrictive cardiomyopathy in a minority, but may contribute to heart failure in a higher proportion (1).
- Cardiac amyloidosis should be suspected in individuals with heart failure and thickened ventricles with grade 2 or greater diastolic dysfunction on echocardiography or typical findings on cardiac magnetic resonance imaging (CMR; diffuse late gadolinium enhancement, ECV expansion or characteristic T-1 relaxation times); diagnosis is confirmed by endomyocardial biopsy and typing of amyloid fibrils as needed.
- Several studies confirm the high sensitivity and specificity of ^{99m}Tc-bone compound scintigraphy (^{99m}Tc-3,3-diphosphono-1,2-propanodicarboxylic acid (DPD) or PYP (2, 3) for cardiac ATTR

amyloidosis; recent studies highlight the value of DPD and/or PYP in differentiating cardiac ATTR from AL amyloidosis (4).

- A distinct advantage of ^{99m}Tc -PYP imaging, even when echocardiography and CMR are diagnostic for cardiac amyloidosis, is its ability to specifically identify ATTR cardiac amyloidosis non-invasively and thereby guide patient management (5).

PATIENT SELECTION

- Individuals with heart failure and unexplained increase in left ventricular wall thickness.
- African-Americans over the age of 60 years with heart failure, unexplained or with increased left ventricular wall thickness (>12 mm).
- Individuals over the age of 60 years with unexplained heart failure with preserved ejection fraction.
- Individuals, especially elderly males, with unexplained neuropathy, bilateral carpal tunnel syndrome or atrial arrhythmias in the absence of usual risk factors, and signs/symptoms of heart failure.
- Evaluation of cardiac involvement in individuals with known or suspected familial amyloidosis.
- Diagnosis of cardiac ATTR amyloidosis in individuals with CMR or echocardiography consistent with cardiac amyloidosis.
- Patients with suspected cardiac ATTR amyloidosis and contraindications to CMR such as renal insufficiency or an implantable cardiac device (5).

OBTAINING THE RADIOTRACER

- ^{99m}Tc -PYP is readily available as unit doses from commercial radiopharmaceutical distributors or as kits for preparation.
- Kits containing 5 or 30 single-use vials are commercially available. Each 10 ml vial contains 11.9 mg of sodium pyrophosphate and 3.2 mg of stannous chloride and 4.4 mg of total tin, and this kit is approved for bone, cardiac (for the detection of myocardial infarction), and blood pool (radionuclide ventriculography and GI bleeding) imaging (see package insert for details of reconstitution of ^{99m}Tc -PYP).
- The total body effective dose from 15 mCi of ^{99m}Tc -PYP is estimated at 3.2 mSv. (6)
- ^{99m}Tc -DPD is not available for clinical use in the United States. Although there are no large studies directly comparing the agents, the principles in this document apply similarly to ^{99m}Tc -DPD and ^{99m}Tc -PYP imaging.

TEST PREPARATION

- No specific test preparation is required.

IMAGING PROCEDURE

- Recommendations for standardized acquisition of ^{99m}Tc -PYP imaging for cardiac amyloidosis are shown in **Table 1**. Individual centers can modify imaging procedures based on local camera capabilities and expertise.
- Planar imaging is rapid, simple to perform, and useful for visual interpretation and quantification of the degree of myocardial uptake (see image interpretation) by heart-to-lung ratio or comparison to rib uptake, but is limited in patients with excess blood pool activity. 1-hour planar only imaging without SPECT is not recommended.
- SPECT (SPECT/CT if available) imaging is may be helpful to
 1. identify overlap of bone uptake
 2. distinguish blood pool activity from myocardial activity (3)
 3. assess the distribution of myocardial ^{99m}Tc -PYP uptake in individuals with positive planar scans
 4. identify ^{99m}Tc -PYP uptake in the interventricular septum (commonly involved in amyloidosis) and
 5. quantify the degree of myocardial uptake by comparison to rib uptake.
- Whole body planar imaging may be helpful to identify uptake of ^{99m}Tc -PYP in the shoulder and hip girdles (a specific sign of systemic ATTR amyloidosis) (7) and should be considered adjunctive and optional in addition to standard cardiac-centered imaging, based on local expertise.
- The value of ^{99m}Tc -PYP imaging with the newer “cardiac only” SPECT cameras needs further validation (due to inability to accurately display bone and lung ^{99m}Tc -PYP uptake with these systems; see image interpretation section). (8)

Table 1. Recommendations for Standardized Acquisition of ^{99m}Tc-PYP/DPD/HMDP for Cardiac Amyloidosis

Imaging procedures	Parameters	Recommendation
Preparation	No specific preparation. No fasting required.	Required
Scan	Rest scan	Required
Dose	^{99m} Tc-PYP: 10-20 mCi (370-740 MBq) intravenously ^{99m} Tc-DPD: 10-20 mCi (370-740 MBq) intravenously ^{99m} Tc-HMDP: 10-20 mCi (370-740 MBq) intravenously	Recommended
Time between injection and acquisition: ^{99m} Tc-PYP/DPD/HMDP	2 or 3 hours	Recommended
Time between injection and acquisition: ^{99m} Tc-PYP only	1 hour	Optional. If excess blood pool activity noted on 1-hour images, 3-hour imaging is recommended. See below regarding image type.
General imaging parameters†		
Field of view	Heart Chest	Required Optional for planar
CT attenuation correction	Heart	Recommended SPECT/CT fusion images helpful to localize tracer uptake to the myocardium
Image type: Planar	Chest 2 or 3 hours	Recommended 1-hour planar-only imaging is not recommended
Image type: SPECT	Heart	Required
Position	Supine Upright	Required Optional

Energy window	140 keV, 15–20%	Required
Collimators	Low energy, high resolution	Recommended
Matrix-Planar	256 x 256	Recommended
Matrix-SPECT	128 x 128 (at least 64 by 64 is required)	Recommended
Pixel size	2.3–6.5 mm	Recommended
Planar imaging specific parameters†		
Number of views*	Anterior and lateral	Required
Detector configuration	90°	Recommended
Image duration (count based)	750,000 counts	Recommended
Magnification	1.46 for large field of view systems	Recommended with goal of achieving recommended pixel size
	1.0 for small field of view systems	Recommended
SPECT imaging specific parameters†		
Angular range/ Detector Configuration	180°/90°	Minimum Required
	360°/180°	Optional, recommended if large FOV camera is available
ECG gating	Off; Non-gated imaging	Recommended
Number of views/ detector	40/32	Recommended
Time per stop	20 seconds / 25 seconds	Recommended
Magnification	1.46 (180° angular range)	Recommended
	1.0 (360° angular range)	

*Anterior and lateral views are obtained at the same time; lateral planar views or SPECT imaging may help separate sternal from myocardial uptake. ECG = electrocardiogram; PYP = pyrophosphate. † = parameters for NaI SPECT scanners.

IMAGE INTERPRETATION

- See **Table 2**. The anterior and lateral planar images as well as the rotating projection images and reconstructed SPECT images are reviewed in standard cardiac imaging planes using commercial software.
- Myocardial ^{99m}Tc -PYP uptake patterns are categorized as absent, focal, diffuse or focal and diffuse.
- When myocardial uptake is visually present on SPECT images H/CL ratios of ≥ 1.5 at one hour are classified as ATTR positive and ratios of < 1.5 ATTR negative (4).

Quantifying Myocardial ^{99m}Tc -PYP Uptake

There are two approaches to quantification (See Table 2):

1. Quantitative Myocardial-to-Contralateral lung uptake ratio at 1 hour

- Circular target regions of interest (ROI) are drawn over the heart on the planar images and are mirrored over the contralateral chest to account for background and ribs (**see Figure 1**).
- Total and absolute mean counts are measured in each ROI. A heart-to-contralateral lung (H/CL) ratio is calculated as the ratio of heart ROI mean counts to contralateral chest ROI mean counts.
- When myocardial uptake is visually present on SPECT images H/CL ratios of ≥ 1.5 at one hour (≥ 1.3 at 3 hours) are classified as ATTR positive and ratios of < 1.5 (< 1.3 at 3 hours) ATTR negative (4).

2. Semi-quantitative: visual comparison to bone (rib) uptake at 3 hours

Cardiac uptake of ^{99m}Tc -PYP is evaluated using a semi-quantitative visual scoring method in relation to bone (rib) uptake (**Table 2 and Figure 2**). Based on previously published results, visual scores of greater than or equal to 2 on planar (2, 3) or SPECT images at 3 hours (7) are classified as ATTR positive, and scores of less than 2 as ATTR negative.

While grade 2 or 3 or H/CL ≥ 1.5 uptake is strongly suggestive of ATTR amyloidosis, any degree of ^{99m}Tc -PYP uptake can also be seen in AL amyloidosis, and as such a complete evaluation is warranted to exclude this diagnosis.

In clinical practice both semi-quantitative visual scoring and H/CL are used.

Table 2. Recommendations for Interpretation ^{99m}Tc-PYP/DPD/HMDP for Cardiac Amyloidosis

Step 1: Visual interpretation	
<ul style="list-style-type: none">Evaluate planar and SPECT images to confirm diffuse radiotracer uptake in the myocardium.Differentiate myocardial radiotracer uptake from residual blood pool activity, focal myocardial infarct, and overlapping bone (e.g., from rib hot spots from fractures) on SPECT images. If excess blood pool activity is noted, recommend repeat SPECT imaging at 3 hours.If myocardial tracer uptake is visually present on SPECT, proceed to step 2, semi-quantitative visual grading. If no myocardial tracer uptake is present on SPECT, the visual grade is 0.	
Step 2: Semi-quantitative visual grading to diagnose ATTR cardiac amyloidosis	
<ul style="list-style-type: none">Examine planar and SPECT images for relative tracer uptake in the myocardium relative to ribs and grade using the following scale:	
Grade 0	No myocardial uptake and normal bone uptake
Grade 1	Myocardial uptake less than rib uptake
Grade 2	Myocardial uptake equal to rib uptake
Grade 3	Myocardial uptake greater than rib uptake with mild/absent rib uptake
Step 3: Heart/Contralateral lung uptake ratio assessment (when applicable)	
<ul style="list-style-type: none">A circular ROI should be drawn over the heart on the anterior planar images with care to avoid sternal overlap and with size adjusted to maximize coverage of the heart without inclusion of adjacent lung. This ROI (same size) should be mirrored over the contralateral chest without inclusion of the right ventricle, to adjust for background and rib uptake (See Figure 1). The heart and contralateral ROIs should be drawn above the diaphragm.A H/CL ratio is calculated as the ratio of heart ROI mean counts to contralateral lung ROI mean counts.H/CL ratios of ≥ 1.5 at one hour can accurately identify ATTR cardiac amyloidosis if myocardial PYP uptake is visually confirmed on SPECT and systemic AL amyloidosis is excluded (9). An H/CL ratio of ≥ 1.3 at 3 hours can identify ATTR cardiac amyloidosis.NOTE: Diagnosis of ATTR cardiac amyloidosis cannot be made solely based on H/CL ratio alone with PYP. H/CL ratio is not recommended if there is absence of myocardial uptake on SPECT. Additionally, if the visual grade is 2 or 3, diagnosis is confirmed, and H/CL ratio assessment is not necessary. H/CL ratio is typically concordant with visual grade. If discordant or the visual grade is equivocal, H/CL ratio may be helpful to classify equivocal visual grade 1 versus 2 as positive or negative.	

See **Figure 2**. Grade 2 or Grade 3 uptake is consistent with ATTR cardiac amyloidosis if a monoclonal plasma cell dyscrasia is excluded, as this degree of uptake can be seen in >20% of patients with AL cardiac amyloidosis.(3) Grade 0 and Grade 1 uptake may be observed in AL cardiac amyloidosis and warrants further evaluation to exclude AL amyloidosis.(3) The writing group would like to emphasize the importance of excluding a monoclonal process with serum/urine immunofixation and a serum-free light-chains assay in all patients with suspected amyloidosis.

Of note: ^{99m}Tc -PYP/DPD/HMDP uptake could be seen in other causes of myocardial injury, including pericarditis, myocardial infarction (regional uptake), and chemotherapy or drug associated myocardial toxicity.

Adapted from the original document (doi:10.1007/s12350-019-01760-6).
(10, 11)

AL = amyloid light chain; ATTR = amyloid transthyretin; H/CL = heart/
contralateral lung; ROI = region of interest.

Figure 1. Quantitation of Cardiac ^{99m}Tc -PYP Uptake Using Heart-to-Contralateral Lung (H/CL) Ratio

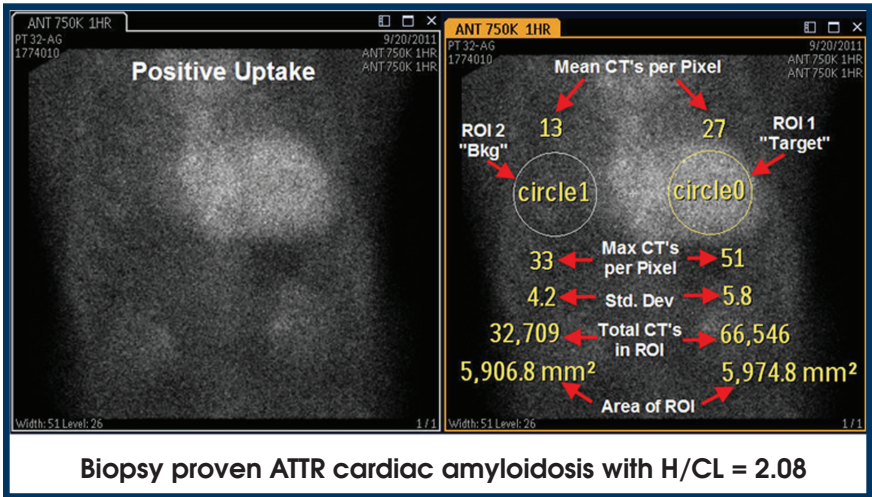
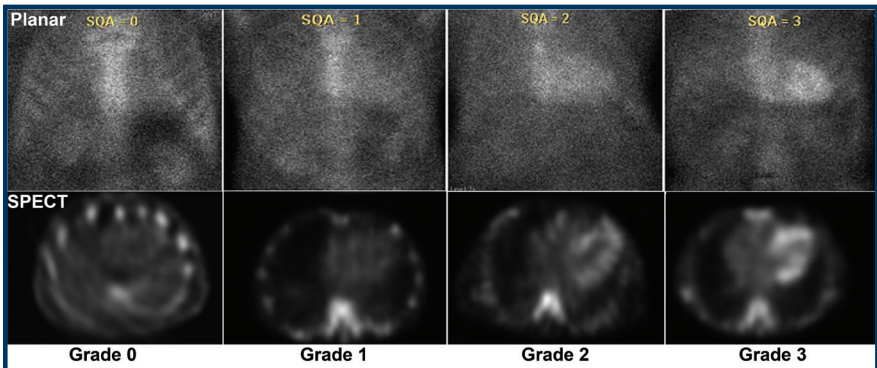


Figure 2. Grading ^{99m}Tc -PYP Uptake on Planar and SPECT Images



REPORTING

The report should include all reference elements of an ideal report as per standard ASNC guidelines. (12)

Table 3. Recommendations for Standardized Reporting of ^{99m}Tc-PYP/DPD/HMDP Imaging for Cardiac Amyloidosis

Parameters	Elements
Demographics	Patient name, age, sex, reason for the test, date of study, prior imaging procedures, biopsy results if available (Required)
Methods	Imaging technique, radiotracer dose and mode of administration, interval between injection and scan, scan technique (planar and SPECT) (Required)
Findings	Image quality Visual scan interpretation (Required) Semi-quantitative interpretation in relation to rib uptake (Required) Quantitative findings H/CL lung ratio (Optional; recommended for positive scans)
Ancillary findings	Whole-body imaging if planar whole-body images are acquired (Optional) Interpret CT for attenuation correction if SPECT/CT scanners are used (Recommended)

<p>Conclusions</p>	<ol style="list-style-type: none"> 1. An overall interpretation of the findings into categories of 1) not suggestive of ATTR cardiac amyloidosis; 2) strongly suggestive of ATTR cardiac amyloidosis; or 3) equivocal for ATTR cardiac amyloidosis after exclusion of a systemic plasma cell dyscrasia. (Required) <ol style="list-style-type: none"> a. Not suggestive: A semi-quantitative visual Grade of 0. b. Equivocal: If diffuse myocardial uptake of ^{99m}Tc-PYP/DPD/HMDP is visually confirmed and the semi-quantitative visual grade is 1 or there is interpretive uncertainty of grade 1 versus grade 2 on visual grading. c. Strongly suggestive: If diffuse myocardial uptake of ^{99m}Tc-PYP/DPD/HMDP is visually confirmed, a semi-quantitative visual grade of 2 or 3. 2. Statement that evaluation for AL amyloidosis by serum FLCs, serum, and urine immunofixation is recommended in all patients undergoing ^{99m}Tc-PYP/DPD/HMDP scans for cardiac amyloidosis. (Required) 3. Statement that results should be interpreted in the context of prior evaluation and referral to a hematologist or amyloidosis expert is recommended if either: a) Recommended echo/CMR is strongly suggestive of cardiac amyloidosis and ^{99m}Tc PYP/DPD/HMDP is not suggestive or equivocal and/or b) FLCs are abnormal or equivocal. (Recommended)
---------------------------	--

AL = amyloid light chain; ATTR = amyloid transthyretin; CMR = cardiovascular magnetic resonance; echo = echocardiography; FLC = free light chain; H/CL = heart-to-contralateral lung ratio.

BILLING

ASNC would recommend:

- For planar with SPECT report CPT 78803 radiopharmaceutical localization of tumor or distribution of radiopharmaceutical agent(s); tomographic (SPECT).
- When reporting CPT 78803, planar imaging of a limited area or multiple areas should be included with the SPECT.
- For the HCPCS level II code report A9538 ^{99m}Tc- pyrophosphate, diagnostic, per study dose, up to 25 millicuries.
- For a single planar imaging session alone (without a SPECT study), report CPT 78800 radiopharmaceutical localization of tumor or distribution of radiopharmaceutical agent(s); limited area.

REFERENCES:

- (1) Ruberg FL, Berk JL. Transthyretin (TTR) cardiac amyloidosis. *Circulation* 2012;126:1286-300.
- (2) Perugini E, Guidalotti PL, Salvi F, Cooke RM, Pettinato C, Riva L et al. Noninvasive etiologic diagnosis of cardiac amyloidosis using ^{99m}Tc-3,3-diphosphono-1,2-propanodicarboxylic acid scintigraphy. *J Am Coll Cardiol* 2005;46:1076-84.
- (3) Gertz MA, Brown ML, Hauser MF, Kyle RA. Utility of technetium Tc 99m pyrophosphate bone scanning in cardiac amyloidosis. *Arch Intern Med* 1987;147:1039-44.
- (4) Bokhari S, Castano A, Pozniakoff T, Deslisle S, Latif F, Maurer MS. (99m)Tc-pyrophosphate scintigraphy for differentiating light-chain cardiac amyloidosis from the transthyretin-related familial and senile cardiac amyloidoses. *Circ Cardiovasc Imaging* 2013;6:195-201.
- (5) Dorbala S, Cuddy S, Falk RH. How to Image Cardiac Amyloidosis: A Practical Approach. *JACC Cardiovasc Imaging* 2020;13(6):1368-1383.
- (6) Einstein AJ, Shuryak I, Castaño A, Mintz A, Maurer MS, Bokhari S. Estimating cancer risk from 99mTc pyrophosphate imaging for transthyretin cardiac amyloidosis. *J Nucl Cardiol* 2020;27(1):215-224.
- (7) Hutt DF, Quigley AM, Page J, Hall ML, Burniston M, Gopaul D et al. Utility and limitations of 3,3-diphosphono-1,2-propanodicarboxylic acid scintigraphy in systemic amyloidosis. *Eur Heart J Cardiovasc Imaging* 2014;15:1289-98.
- (8) Flaherty KR, Morgenstern R, Pozniakoff T, DeLuca A, Castano A, Maurer MS, et al. 99mTechnetium pyrophosphate scintigraphy with cadmium zinc telluride cameras is a highly sensitive and specific imaging modality to diagnose transthyretin cardiac amyloidosis. *J Nucl Cardiol* 2020;27(2):371-380.
- (9) Castano A, Haq M, Narotsky DL, Goldsmith J, Weinberg RL, Morgenstern R, et al. Multicenter study of planar technetium 99m pyrophosphate cardiac imaging: Predicting survival for patients with ATTR cardiac amyloidosis. *JAMA Cardiol* 2016;1:880-9.

- (10) Dorbala S, Ando Y, Bokhari S, Dispenzieri A, Falk RH, Ferrari VA, et al. ASNC/AHA/ASE/EANM/HFSA/ISA/SCMR/SNMMI expert consensus recommendations for multimodality imaging in cardiac amyloidosis: Part 1 of 2—evidence base and standardized methods of imaging. *J Nucl Cardiol* 2019;26(6):2065-2123.
- (11) Dorbala S, Ando Y, Bokhari S, Dispenzieri A, Falk RH, Ferrari VA, et al. Addendum to ASNC/AHA/ASE/EANM/HFSA/ISA/SCMR/SNMMI expert consensus recommendations for multimodality imaging in cardiac amyloidosis: Part 1 of 2—evidence base and standardized methods of imaging. *J Nucl Cardiol* 2021 (in press).
- (12) Tilkemeier PL, Bourque J, Doukky R, Sanghani R, Weinberg RL. ASNC imaging guidelines for nuclear cardiology procedures: Standardized reporting of nuclear cardiology procedures. *J Nucl Cardiol* 2017;24(6):2064-2128.

ASNC thanks the following members for their contributions to this document:

Writing Group:

Sharmila Dorbala, MD, MPH (Chair)

Sabahat Bokhari, MD

Jamieson Bourque, MD, MHS

Edward Miller, MD, PhD

Renee Bullock-Palmer, MD

Prem Soman, MD, PhD

Randall Thompson, MD

Reviewers:

Rodney Falk, MD

Martha Grogan, MD

Matthew Maurer, MD

Frederick Ruberg, MD

Version History:

First Issued: February 2016

Present Version (Version 3.0): updated March 2021.

Sponsorship: Publication and distribution of this document has been made possible by corporate support from Pfizer. Corporate supporters are not involved in the creation or review of information contained in ASNC Practice Points update.

Copyright © 2021 American Society of Nuclear Cardiology



American Society of Nuclear Cardiology

www.asnc.org



ASNC APP



Pfizer provided support for this project but had no input into the educational content of the Cardiac Amyloidosis Practice Points update

PP-R1D-USA-0940

August 2021